

False Rifampicin Resistance in Xpert Ultra Applied to Lymph Node Aspirate: A Case Report

Kamela C. S. Ng,^{1,2} Leen Rigouts,¹ Bouke C. de Jong,¹ and Lutgarde Lynen³

¹Mycobacteriology Unit, Department of Biomedical Sciences, Institute of Tropical Medicine, Antwerp, Belgium, ²Department of Global Health and Social Medicine, Harvard Medical School, Boston, Massachusetts, United States, and ³HIV/TB Unit, Department of Clinical Sciences, Institute of Tropical Medicine, Antwerp, Belgium

A 36-year-old male patient was diagnosed with tuberculosis in Antwerp, Belgium, in May 2018. His lymph node aspirate initially tested rifampicin resistant in Xpert MTB/RIF Ultra, but tested susceptible in all other tests including targeted deep sequencing due to a rare matrix effect in the Xpert MTB/RIF Ultra reaction tube.

Keywords. extrapulmonary tuberculosis; false mutant melting temperature; false rifampicin resistance; lymph node; Xpert Ultra.

A 36-year-old male patient without significant medical history was admitted to a hospital in Antwerp, Belgium, in March 2018 with fever, weight loss, shortness of breath, and fatigue after visiting his family in Morocco. The computed tomography (CT) scan of his thorax revealed an anterior mediastinal mass, enlarged hilar and mediastinal lymph nodes, and bilateral ground glass infiltrates. The patient was diagnosed with HIV (CD4+ T-cell count of 25 [4.1%]) and *Pneumocystis jirovecii* pneumonia and was started on Tivicay (dolutegravir), Truvada (emtricitabine/tenofovir disoproxil fumarate), and a course of cotrimoxazole and steroids. He was discharged with symptom relief. A month after the initial symptoms, the patient presented with vomiting, chest pain, and odynophagia and was admitted to another hospital. He was diagnosed with seborrheic eczema, a small Kaposi's sarcoma lesion on the arm, and a cytomegalovirus esophagitis.

He was again hospitalized at the end of May 2018 in Brussels, and a transthoracic aspirate was obtained from an affected

lymph node. The aspirate tested 2+ positive for acid fast bacilli by Ziehl Neelsen microscopy (Supplementary Table 1). Growth of *Mycobacterium tuberculosis* was detected in Löwenstein-Jensen medium after 2 weeks. This positive culture, subsequently tested with a Mycobacteria Growth Indicator Tube (MGIT), was sensitive to rifampicin, isoniazid, pyrazinamide, and ethambutol. The patient was then initiated on first-line therapy with isoniazid, rifampicin, pyrazinamide, and ethambutol (HRZE), along with Tivicay, Truvada, and cotrimoxazole.

He was re-admitted in June 2018 with a left supraclavicular abscess. Purulent material was collected from the supraclavicular mass by fine needle aspiration (FNA), and he was restarted on steroids for presumptive TB immune reconstitution syndrome. The aspirate tested 3+ positive for acid fast bacilli. The same sample was tested using Cepheid GeneXpert Systems Xpert MTB/RIF Ultra (Ultra). This assay confirmed the presence of *M. tuberculosis* and, unexpectedly, detected rifampicin resistance (RR). An Ultra rpoB3 mutant melting temperature of 71.7°C suggested the presence of mutation His445Gln based on an Ultra validation study [1]. Further, the presence of both rpoB3 wild-type (WT) and mutant melting temperatures suggested possible rifampicin heteroresistance in the patient's sample [2, 3].

Consistent with the results of the first sample, the same lymph node aspirate was found fully sensitive to TB drugs, including rifampicin (WT), when tested by GenoType MTBDR_{plus} and GenoType MTBDR_{sl}, version 2.0 (LPA-Hain first and second line), Sanger rpoB sequencing, Deeplex MycTB targeted deep sequencing (Genoscreen, Lille, France), and phenotypic drug susceptibility testing on the isolate that grew after 40 days. None of the molecular assays, performed directly on the clinical sample, revealed heteroresistance; no mixed patterns, double peaks, or minority variant populations were observed on LPA-Hain, Sanger sequencing, or Deeplex. Meanwhile, the patient was continued on HRZE, Medrol (methylprednisolone), and antiviral treatment.

Ultra was repeated on a positive MGIT subculture of the patient's fine needle lymph node aspirate at 10⁻² dilution, per the manufacturer's instruction, which returned a rifampicin-susceptible result. Spoligotype analysis on the DNA remnant from the original RR Ultra cartridge showed the same Haarlem pattern as the 1 obtained from culture, indicating that sample switch was highly unlikely.

Given the persistent supraclavicular lymph node swelling, the steroid dose was increased after an initial tapering in July. The HRZE intensive phase was prolonged to 3 months, after which treatment was switched to the HR continuation phase, and the steroids were tapered. Repeat CT thorax showed persistent mediastinal lymphadenopathy and confluent lymph nodes, with

Received 14 February 2020; editorial decision 26 May 2020; accepted 29 May 2020.

Correspondence: Kamela C. S. Ng, PhD, MSc, Department of Global Health and Social Medicine, Harvard Medical School, 641 Huntington Avenue, Boston, MA 02115 (kamela_ng@hms.harvard.edu).

Open Forum Infectious Diseases®

© The Author(s) 2020. Published by Oxford University Press on behalf of Infectious Diseases Society of America. This is an Open Access article distributed under the terms of the Creative Commons Attribution-NonCommercial-NoDerivs licence (<http://creativecommons.org/licenses/by-nc-nd/4.0/>), which permits non-commercial reproduction and distribution of the work, in any medium, provided the original work is not altered or transformed in any way, and that the work is properly cited. For commercial re-use, please contact journals.permissions@oup.com
DOI: 10.1093/ofid/ofaa204

spontaneous drainage. A swab from this drainage was smear-microscopy- and culture-negative and yielded “MTB trace” [2] and “RIF indeterminate” Ultra results.

Considering all test results obtained, we conclude that the patient did not have RR-TB despite the Ultra RR result. Cepheid (Sunnyvale, CA, USA) reviewed the gxx files and agreed with the interpretation as false resistance, while explaining that Ultra is validated on sputum samples, with testing on lymph node aspirate considered off-label use. Nevertheless, similar to the use of Xpert MTB/RIF, the World Health Organization (WHO) recommends the Ultra for testing of selected extrapulmonary specimens (cerebrospinal fluid, lymph nodes, and tissue) [4]. Further, previous studies revealed improved sensitivity for Ultra vs Xpert MTB/RIF Classic (G4) and 100% specificity of Ultra for detecting *M. tuberculosis* in extrapulmonary TB samples including abscess aspirates, lymph nodes, and FNA tissues [5, 6].

Cepheid attributes the false Ultra RR result to a rare matrix effect (akin to a bubble) in the reaction tube that distorted first derivative melt curves to falsely appear as double peaks (Figure 1). Only Cepheid can extract fluorescence data corresponding with melting temperatures from raw gxx files, on request. Xpert Ultra users with administrative privileges can only access the numerical melt peak temperatures of the different probes, whereas fluorescence values that correspond with the melting temperatures are necessary to generate the melt curves.

Cepheid has not received prior reports of similar errors, making this a very rare event. The patient completed the remaining TB treatment uneventfully. He gained 8 kg and is doing well.

Summarizing the diagnostic flow for this patient, the Ultra RR result triggered further molecular resistance typing for other TB drugs. The LPA performed for isoniazid resistance testing—which also includes the same *rpoB* target as the Ultra—did not show any rifampicin resistance conferring mutation, raising doubt on the Ultra RR result. This prompted further testing to exclude heteroresistance and sample switch. Repeat Ultra on a diluted positive MGIT subculture confirmed that the initial RR was false.

Despite excellent specificity of the WHO-endorsed molecular rifampicin resistance tests, the WHO recommends that patients diagnosed with RR, who have a low pretest probability, such as our patient, should have the resistance test repeated on a second sample before initiating MDR-TB treatment, also to address potential clerical errors. In our patient, initial sampling was invasive and not repeated until later, when spontaneous drainage took place and the bacterial burden became too low for a valid rifampicin resistance result. Given that this false Ultra RR result was a rare event, repeat testing on a new sample would likely also have yielded a correct RS result. Nevertheless, this case report highlights the importance of documenting postimplementation experience with Ultra specificity for RR. Such experience gained by (reference) laboratories will be augmented when end users have access to analytical tools that reveal the melt peak temperatures and fluorescence data contained in the gxx files necessary to generate the melt curves.

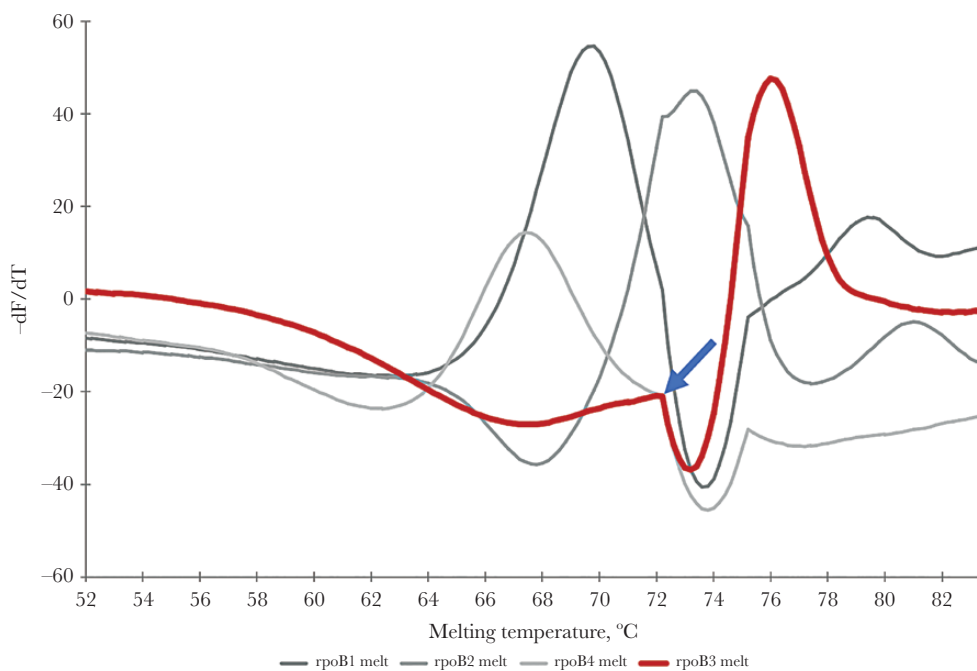


Figure 1. The distorted first derivative melt curve, marked by the arrow, resulted in false mutant melting temperature of Xpert Ultra probe rpoB3.

Supplementary Data

Supplementary materials are available at *Open Forum Infectious Diseases* online. Consisting of data provided by the authors to benefit the reader, the posted materials are not copyedited and are the sole responsibility of the authors, so questions or comments should be addressed to the corresponding author.

Acknowledgments

We thank Soumi Chakravorty of Cepheid for extracting the fluorescence data linked with the melting temperatures from the raw gxx file and for helpful discussion and Gabriela Torrea for helpful comments.

Financial support. K.C.S.N. was supported by Erasmus Mundus Joint Doctorate Fellowship grant 2016-1346, and L.R. and B.d.J. were supported by an European Research Council starting grant INTERRUPTB (Estimating the effective reproductive rate of *M. tuberculosis* from changes in molecular clustering rates, to measure the impact of public health interventions on TB transmission).

Potential conflicts of interest. All authors: no reported conflicts of interest. All authors have submitted the ICMJE Form for Disclosure of Potential Conflicts of Interest. Conflicts that the editors consider relevant to the content of the manuscript have been disclosed.

References

1. Ng KCS, van Deun A, Meehan CJ, et al. Xpert ultra can unambiguously identify specific rifampin resistance-conferring mutations. *J Clin Microbiol* **2018**; 56:e00686–18.
2. Chakravorty S, Simmons AM, Rowneki M, et al. The new Xpert MTB/RIF ultra: improving detection of *Mycobacterium tuberculosis* and resistance to rifampin in an assay suitable for point-of-care testing. *MBio* **2017**; 8:e00812–17.
3. Ng KCS, Supply P, Cobelens FGJ, et al. How well do routine molecular diagnostics detect rifampicin heteroresistance in *Mycobacterium tuberculosis*? *J Clin Microbiol* **2019**; 57:e00717–19.
4. World Health Organization. WHO meeting report of a technical expert consultation: non-inferiority analysis of Xpert MTB/RIF ultra compared to Xpert MTB/RIF. Available at: <https://apps.who.int/iris/bitstream/handle/10665/254792/WHO-HTM-TB-2017.04-eng.pdf?jsessionid=8F7680335B1A3C60BBAF0902C716D2DE?sequence=1>. Accessed 3 January 2018.
5. Perez-Risco D, Rodriguez-Temporal D, Valledor-Sanchez I, et al. Evaluation of the Xpert MTB/RIF ultra assay for direct detection of *Mycobacterium tuberculosis* complex in smear-negative extrapulmonary samples. *J Clin Microbiol* **2018**; 56:e00659–18.
6. Wu X, Tan G, Gao R, et al. Assessment of the Xpert MTB/RIF ultra assay on rapid diagnosis of extrapulmonary tuberculosis. *Int J Infect Dis* **2019**; 81:91–6.