

Research Paper

Cite this article: Nguyen TTM, Dermauw V, Noh J, Chien NH, Dao TTH, Nguyen TGT, Van Hul A, Dorny P (2020). Occurrence of *Taenia* species in pigs in slaughterhouses in Phu Tho province, northern Vietnam. *Journal of Helminthology* **94**, e201, 1–7. <https://doi.org/10.1017/S0022149X20000863>

Received: 11 June 2020

Accepted: 15 September 2020


Key words:

Cysticercosis; *Taenia*; *Spirometra*; pig; slaughterhouses; Vietnam

Author for correspondence:

P. Dorny, E-mail: pdorny@itg.be

Occurrence of *Taenia* species in pigs in slaughterhouses in Phu Tho province, northern Vietnam

T.T.M. Nguyen^{1,2,3}, V. Dermauw², J. Noh⁴, N.H. Chien⁵, T.T.H. Dao⁶,
T.G.T. Nguyen⁶, A. Van Hul² and P. Dorny^{2,3} 

¹National Center for Veterinary Diagnosis, Tan Chung Chua, Hien Ninh, Soc Son, Hanoi, Vietnam; ²Institute of Tropical Medicine, Department of Biomedical Sciences, Nationalestraat 155, 2000 Antwerp, Belgium; ³Ghent University, Faculty of Veterinary Medicine, Salisburylaan 133, 9820 Merelbeke, Belgium; ⁴Centers for Disease Control and Prevention, Parasitic Diseases Branch, Atlanta, America; ⁵Vietnam National University of Agriculture, Faculty of Veterinary Medicine, Trau Quy, Hanoi, Vietnam and ⁶National Institute of Veterinary Research, 86 Truong Chinh Street, Phuong Mai, Dong Da, Hanoi, Vietnam

Abstract

Pigs act as the intermediate hosts of the zoonotic tapeworms *Taenia solium* and *Taenia asiatica*, as well as of the non-zoonotic *Taenia hydatigena*. In Vietnam, human taeniasis and cysticercosis have been reported throughout the country; however, data on porcine cysticercosis are scarce. Our study aimed to estimate the prevalence of *Taenia* spp. in slaughtered pigs in two districts in Phu Tho, a mountainous province in northern Vietnam from where neurocysticercosis patients commonly originate. The carcasses of 399 pigs from 51 small-scale abattoirs were checked for cysticerci, while tongue, liver, masseter muscles, diaphragm and heart were sliced and examined. Retrieved cysticerci underwent polymerase chain reaction–restriction fragment length polymorphism and sequencing for species confirmation. Blood was also collected to detect antibodies by lentil lectin-purified glycoprotein enzyme-linked immunoelectrotransfer blot (LLGP-EITB) and recombinant T24H antigen (rT24H)-EITB and circulating antigens by B158/B60 Ag-ELISA. In two pigs, *T. asiatica* cysticerci were found, confirming the presence of the parasite in pigs in Vietnam at a low prevalence (0.5%; 95% exact confidence interval (CI): 0–1.19%). Cysticerci of *T. solium* were found in none of the pigs, although one serum sample was positive for antibodies in both LLGP-EITB and rT24H-EITB. Furthermore, a high prevalence of *T. hydatigena* cysticercosis was observed (18.0%; 95% Wilson score CI: 14.6–22.1%). In more than half of the *T. hydatigena*-positive pigs, circulating antigens were detected by Ag-ELISA, confirming that this test cannot be used to diagnose *T. solium* cysticercosis in this region. Finally, *Spirometra erinaceieuropaei* was found in one pig liver. It is the first record of this zoonotic cestode species in pigs in Vietnam. Overall, the findings confirmed the complex epidemiology of *Taenia* spp. in pigs in Vietnam.

Introduction

Pigs serve as the intermediate hosts of the zoonotic cestodes *Taenia solium* and *Taenia asiatica*, the former being endemic in many developing regions, while the latter is restricted to some Asian countries (Michelet & Dauga, 2012). Humans can acquire taeniasis, the establishment of an adult tapeworm in the small intestine, by eating raw or undercooked infected pig products: pork (*T. solium*) or pig offal (*T. asiatica*). Human infections with *T. asiatica* are restricted to taeniasis, yet, when humans ingest eggs of *T. solium*, they may also acquire human cysticercosis, the development of the *T. solium* metacestode larval stage (cysticercus) in tissues such as muscles, eyes and brain, the latter referred to as neurocysticercosis (NCC). Infections with *T. solium* cause a high burden in many developing countries, including an estimated 28,000 deaths globally in 2010 (WHO, 2015), and as a consequence, *T. solium* was ranked first on the list of foodborne parasites of concern (FAO/WHO, 2012).

Vietnam is recognized as endemic for zoonotic tapeworms (World Health Organization, 2014), and taeniasis and cysticercosis are considered to be important public health problems in the country (Trung *et al.*, 2013). Human taeniasis and cysticercosis have been reported in 50 out of 63 provinces, with a prevalence of cysticercosis ranging between 0% in Hai Duong and 13% in Ha Giang provinces, both in northern Vietnam; and a prevalence of taeniasis between 0.11% in Hoa Binh (in the north) and 10% in Kon Tum (in the central highlands) (De *et al.*, 2014; Ng-Nguyen *et al.*, 2017). Among the three species that cause taeniasis – *T. solium*, *Taenia saginata* and *T. asiatica* – *T. asiatica* was the most recent species to be confirmed in Vietnamese people (Le *et al.*, 2002).

Pork is the most popular meat type in the country; about 3.8 million tons of pork are produced annually (Vietnam Livestock Production, 2018). Small-scale traditional pig farms are still predominant, contributing to at least 80% of the total pork production (Lapar *et al.*, 2012; Nga *et al.*, 2014). The common habit of eating raw or undercooked pork and organs is one of the main risk factors for acquiring pig-related taeniasis in Vietnam (Somers *et al.*, 2007; Ng-Nguyen *et al.*, 2017). Nevertheless, data on porcine cysticercosis are scarce. The prevalence of porcine *T. solium* cysticercosis was estimated at 0.04%, 0.03% and 0.09% in Hanoi, northern and southern provinces, respectively, as determined by routine meat inspection (Trieu, 2012), while the seroprevalence of porcine cysticercosis in Daklak province, in the central highlands, was estimated at 0.94% using the lentil lectin-purified glycoprotein enzyme-linked immunoelectrotransfer blot (LLGP-EITB) assay (Ng-Nguyen *et al.*, 2018). Until now, *T. asiatica* cysticercosis has not been confirmed in pigs in Vietnam, although the adult intestinal parasite was found in humans (Somers *et al.*, 2007).

Pigs also serve as intermediate hosts of *Taenia hydatigena*, a non-zoonotic tapeworm species, which uses dogs as their definite hosts. This parasite was reported to be highly prevalent in pigs in Asia (Nguyen *et al.*, 2016). In Vietnam, the prevalence of *T. hydatigena* was estimated at 31.8% in southern provinces and 25.1% in northern Vietnam (Huan, 1994; Lan *et al.*, 2011). This parasite is reported to cause cross-reactions in serological tests used for diagnosis of *T. solium* cysticercosis in pigs (Dorny *et al.*, 2004). In regions where the prevalence of *T. hydatigena* in pigs is high, serological tests that are prone to cross-reactions should not be used to diagnose zoonotic cysticercosis. The diagnostic performance of serological tests to detect *T. solium* cysticercosis in pigs has not yet been assessed in Vietnam.

Therefore, we performed a cross-sectional survey in pig abattoirs in Phu Tho province, northern Vietnam, aiming to determine the prevalence of *Taenia* species and to assess the diagnostic performance of serological methods for *T. solium* cysticercosis in pigs.

Materials and methods

Study area

Our study was conducted in Tan Son and Yen Lap districts of Phu Tho province (fig. 1). This province is located in the northern mountainous region of Vietnam and shares a border with Hanoi in the west. About 1.4 million people belonging to 34 ethnic groups are dwelling over an area of 3528.1 km² (GSO, 2019). In Phu Tho province, the pig husbandry system is representative for the midland area, including both traditional smallholder farms and commercial farms. The pig population is estimated to be around 800,000; in 2017, 128.2 thousand tons of pork were produced for local consumption or export (SDAH, 2018), ranking seventh out of 24 northern provinces (Vietnam Livestock Production, 2018). Furthermore, this province was reported to have a high prevalence of human taeniasis (8.68% by the Kato-Katz method) (Vien *et al.*, 2013). The habit of eating undercooked pork and liver is common, especially ‘*thit lon chua*’ (fermented pork), ‘*gan tai*’ (rare liver) and ‘*gan nuong*’ (grilled liver) (Vien *et al.*, 2013). At the clinic of the National Institute of Malariaology, Parasitology and Entomology (NIMPE) in Hanoi, NCC patients frequently originate from Phu Tho province.

In Tan Son, one of our study districts, a preliminary study on *Taenia* spp. infection in humans estimated that 7.3% and 1.2% of

the population had antibodies and circulating antigens, respectively (NIMPE, unpublished results). However, no data on *Taenia* spp. in pigs are available. Yen Lap is a neighbouring district of Tan Son in the high mountain region of Phu Tho province. In both districts, ethnic minorities account for more than 70% of the population and pork is mainly sold on wet markets.

Study design

We conducted a cross-sectional survey between July and August 2018. Three study sites per district were chosen based on convenience of sample collection (e.g. being able to purchase the entire visceral organs). The three communes, Thu Ngac, My Thuan, Tan Phu were selected in Tan Son, while in Yen Lap, two communes, Xuan Vien, Xuan Thuy, and one town, Yen Lap town, were chosen.

A list of pig abattoirs in the six sites was requested from the District Veterinary Station of the Sub-Department of Animal Health in Phu Tho. The owners of all 76 abattoirs were informed about the study objectives, and invited to participate in the study. All abattoirs were small-scale enterprises processing few pigs per day. A total of 51 out of 76 abattoir owners agreed to take part in the study. Once approval was granted, the slaughterhouse was visited, and the process of the study was explained to the owners before sampling. Next, blood samples were taken immediately after slaughter of the pigs. The slaughterers performed a routine check of the abdominal cavity and meat cutting as ‘informal inspection’; no official meat inspection is performed in abattoirs in this region. All visible cysts and suspected lesions were collected and transferred to vials containing ethanol 70%. The liver, heart, tongue, masseter muscles and diaphragm were collected from the same pigs. Blood and tissues were transported to the lab in cool boxes. Blood was allowed to clot, serum was separated and stored at –20°C until further analysis.

Laboratory analysis

Dissection

The collected tissues were cut into slices of less than 0.5 cm and examined for cysticerci. Cysts detected on incisional and intact surfaces were visually classified as one of the *Taenia* species being *T. solium*, *T. hydatigena* and *T. asiatica* (Dorny *et al.*, 2004). Detected cysts were collected in separate tubes for each tissue and stored in 70% ethanol. Suspected lesions presenting as small white spots in the liver were also collected and stored in 70% ethanol.

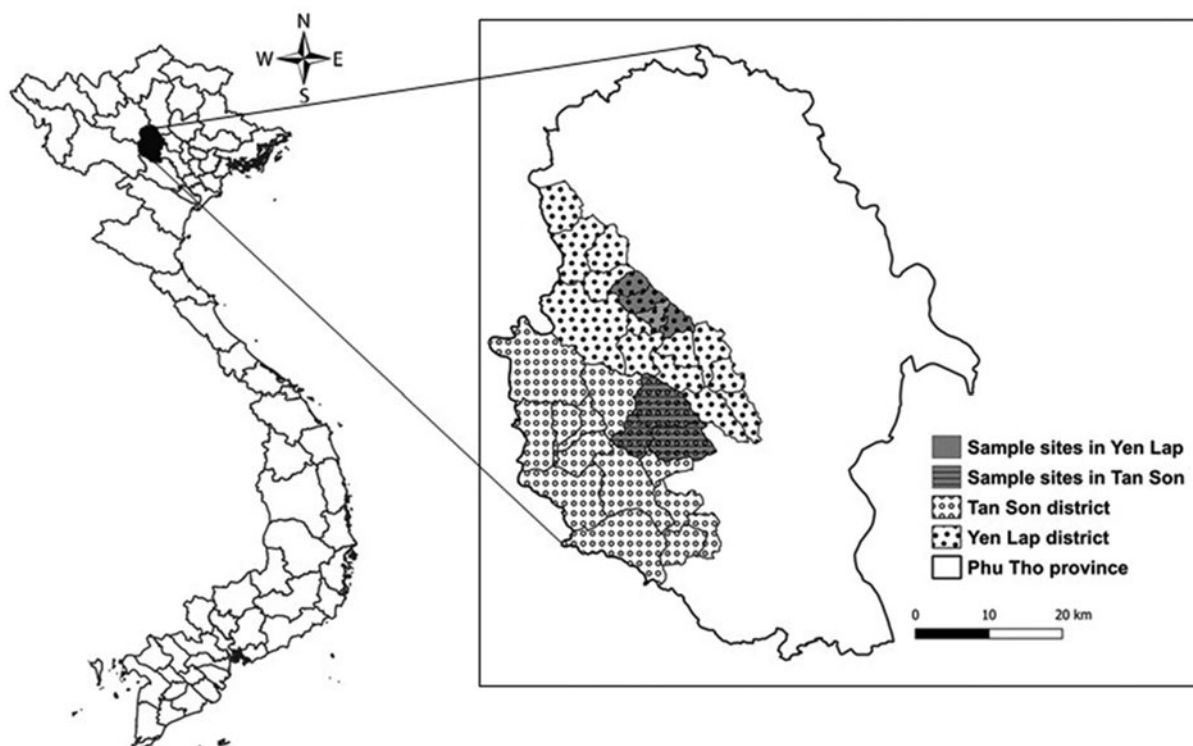
Molecular techniques

Genomic DNA was extracted from all collected cysts and suspected lesions using the DNeasyBlood and Tissue Extraction Kit according to the manufacturers’ instructions (QIAGEN, Hilden, Germany). Polymerase chain reaction–restriction fragment length polymorphism (PCR-RFLP) targeting a mitochondrial 12 s ribosomal DNA fragment was used to differentiate the *Taenia* spp. using procedures described by Rodriguez-Hidalgo *et al.* (2002) and Devleeschauwer *et al.* (2013). Species confirmation was done by sequencing of the PCR products at the VIB Genetic Service Facility (University of Antwerp, Belgium). The sequences were edited and aligned using BioEdit (Hall, 1999), BLAST was performed on National Center for Biotechnology Information and the sequences were submitted to GenBank.

Table 1. Number of pigs harbouring cysticerci and suspected lesions in different organs based on meat inspection and dissection.

Methods	Sites	<i>Taenia solium</i> cysticerci	<i>Taenia hydatigena</i> cysticerci	<i>Taenia asiatica</i> cysticerci	Other suspected lesions ^a	Total
Inspection	Abdominal cavity	-	30	-	-	30
	Liver surface	-	15	-	-	15
Dissection	Tongue	0	-	-	-	0
	Heart	0	-	-	-	0
	Liver	0	15	0	74	89
	Masseters	0	-	-	-	0
	Diaphragm	0	-	-	-	0
Total no. of pigs		0	41	0	74	115

^aWhite solid spots in the liver of 1 mm or less.

**Fig. 1.** Map of Vietnam showing Phu Tho province and the location of the study sites.

Serological tests

Serum samples were examined for circulating *Taenia* spp. antigens using a commercial B158/B60 Ag-ELISA kit (apDia Turnhout, Belgium), following the manufacturer's instructions. Detection of specific antibodies to *T. solium* was performed using the LLGP-EITB, using native antigen extracts, and a EITB using a recombinant T24H antigen (rT24H-EITB) at the Centers for Disease Control and Prevention, Atlanta, USA (Tsang *et al.*, 1989; Noh *et al.*, 2014).

Sample size

We assumed a large population size with unknown prevalence of *Taenia* spp. cysticercosis in pigs (due to the absence of data on the

prevalence of *T. asiatica* cysticercosis in pigs), a required confidence level of 95% and a desired precision of 5% (Martin *et al.*, 1987). The planned sample size for the study was 384. Ultimately, 399 pigs were sampled from 51 abattoirs in Phu Tho.

Statistical analysis

All collected data were entered in Excel (Microsoft Office 2016, Microsoft Corporation, Washington, USA). A descriptive analysis of the occurrence of the different *Taenia* spp. was conducted. The prevalence of *Taenia* spp. and the associated 95% Wilson score confidence intervals (CIs) were calculated. In case of low cell counts, the Clopper–Pearson exact CIs were calculated. All

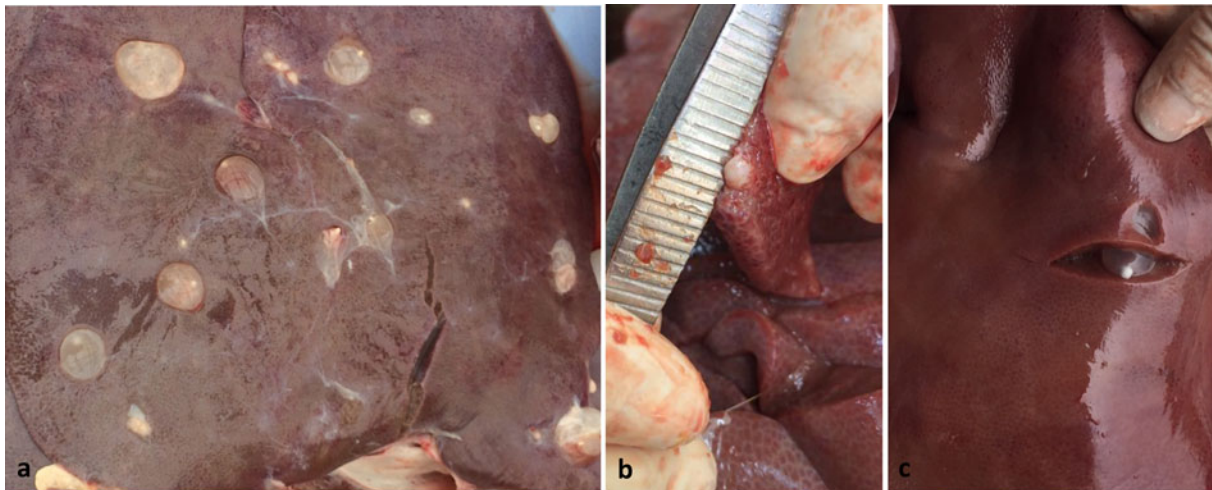


Fig. 2. (a) *Taenia hydatigena* cysticerci on the liver surface; (b) white spot in the liver; (c) and *T. hydatigena* cyst under the liver surface.

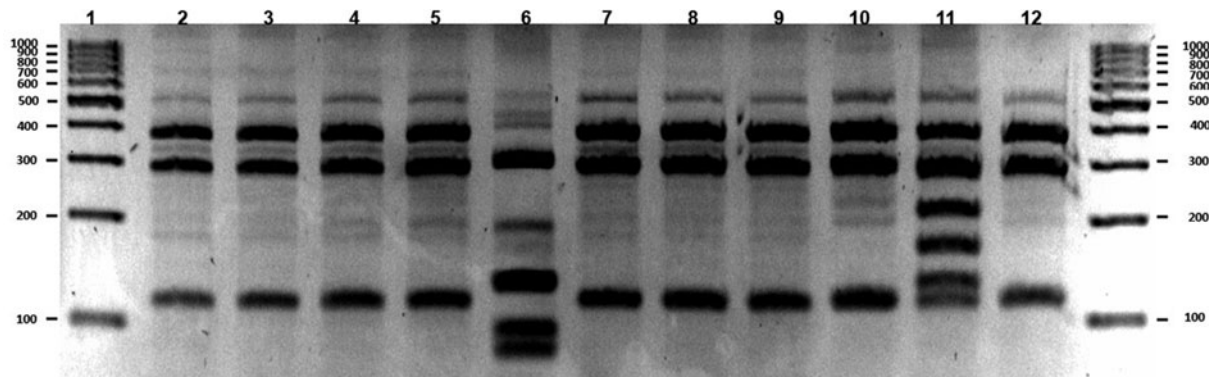


Fig. 3. PCR-RFLP results of suspected lesions in pigs sampled in Phu Tho, Vietnam. Lane 1: DNA ladder; lane 12: *Taenia hydatigena* – positive control; lanes 2–5, 7–10 (385, 289, 114 bp): *T. hydatigena*; lane 11 (393, 295, 218, 169, 130, 116 bp): *T. asiatica*; lane 6 (309, 190, 131, 100 bp): *Spirometra erinaceieuropaei*.

statistical analyses were conducted using R software (R Core Team, 2020).

Results

Informal inspection results

A total of 399 pigs from 51 abattoirs in Yen Lap and Tan Son districts, Phu Tho province were examined for cysticerci by slaughterers (table 1). Forty-one pigs (41/399, 10.8%) carried cysts consistent with the morphology of *T. hydatigena* cysticerci (i.e. large, visceral, fluid-filled cysts with a single white scolex) in the abdominal cavity and/or on the surface of abdominal organs. Among them, 15 pigs had *T. hydatigena* cysticerci on the liver surface only (fig. 2a).

Dissection results

Tongue, heart, liver, diaphragm and masseter muscles of all 399 pigs were dissected (table 1). No cysticerci of *T. solium* were detected. In 74 pigs, lesions without a clear diagnosis (small white solid spots, diameter smaller than or equal to 1 mm) were detected in the liver (fig. 2b). In one pig, a cyst (visceral,

fluid-filled cyst of 1 cm in diameter with a single white scolex), perceived to be *T. hydatigena* due to its large size, was found inside the liver close to the surface (fig. 2c); and in the same pig, cysticerci consistent with the morphology of *T. hydatigena* were detected during inspection by slaughterers in the abdominal cavity.

Molecular results

Suspected lesions from 74 pigs and *T. hydatigena* cysticerci from 41 pigs were further analysed by PCR followed by RFLP. Cysticerci consistent with the morphology of *T. hydatigena* detected in 41 pigs were all confirmed to be *T. hydatigena*. Suspected lesions detected in 31 pig livers were also identified as *T. hydatigena*. Thus, the total number of pigs infected with *T. hydatigena* was 72 and the prevalence was estimated at 18.0% (95% Wilson score CI: 14.6–22.1%). Suspected lesions in two pigs showed four bands (100, 131, 190, 309 bp) in RFLP, consistent with *T. asiatica* (fig. 3), which were confirmed by sequencing (GenBank accession numbers MT448955.1 and MT463535.1). The prevalence of *T. asiatica* was estimated at 0.50% (95% exact CI: 0.06–1.80%). One suspected lesion collected from a pig liver revealed four bands (309, 190, 131, 100 bp) in RFLP and was

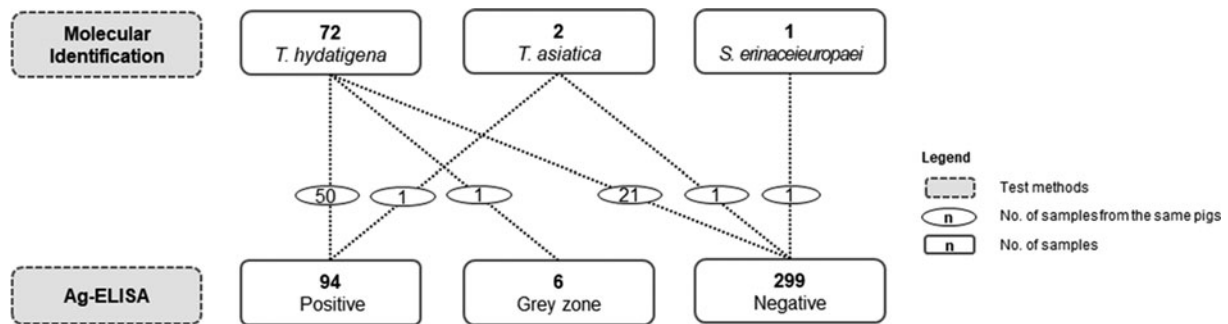


Fig. 4. The results of Ag-ELISA and molecular analysis of cysts detected in pig samples in Phu Tho, Vietnam.

identified to be *Spirometra erinaceieuropaei* by sequencing (GenBank accession number MT465993.1). No *T. solium* cysticerci were detected by morphological nor molecular identification in the 399 sampled pigs.

Serological test results

The Ag-ELISA identified 94/399 (23.6%) of pigs as positive for circulating cysticercus antigens, while 6/399 (1.5%) of the results were doubtful (grey zone) and 299/399 (74.9%) were negative (fig. 4). Cysticerci of *T. hydatigena* or *T. asiatica* were identified in 51/94 of sero-positive pigs (54.3%), with *T. hydatigena* being identified in 50/94 (53.2%). Conversely, the Ag-ELISA was negative in 22/74 (29.7%) of pigs found to harbour *T. hydatigena* or *T. asiatica* cysts. One pig with a doubtful Ag-ELISA result (grey zone) was found to harbour *T. hydatigena* cysts. The serum of the *S. erinaceieuropaei*-positive pig was negative in the Ag-ELISA. Overall, *T. hydatigena* confirmed cases were Ag-ELISA positive in 50 out of 72 (69.4%) pigs and serum of one out of two (50.0%) pigs infected with *T. asiatica* was positive.

The serum of 1/399 (0.3%) pig, positive in Ag-ELISA, was also positive in LLGP-EITB, with bands at GP50 and GP42, and in the rT24H-EITB test. This serum originated from a pig with many *T. hydatigena* cysts on the liver. All other serum samples were negative in both LLGP-EITB and rT24H-EITB tests.

Discussion

Our study is the first to confirm the presence of *T. asiatica* cysticerci in pigs in Vietnam. This finding completes the life cycle of this parasite in the country. Previously, only intestinal *T. asiatica* tapeworms were found in humans (Le *et al.*, 2002). However, the typical cysticerci of *T. asiatica*, cystic or oval-shaped, with a length of 1.9–3.0 mm and a thin and transparent cyst wall, as described by Eom *et al.* (2002, 2020), were not observed in this study. The two molecularly confirmed cases of *T. asiatica* presented as small, white, round spots in the liver. Fan *et al.* (1990, 1992) stated that *T. asiatica* cysticerci start calcification 45 days post inoculation and present as calcified spots in the liver only six months post inoculation. This type of hepatic lesion can easily be missed during meat inspection or confused with other parasites such as *T. hydatigena*, or lesions caused by migrating *Ascaris suum* larvae (so-called ‘milk spots’) (Polley & Mostert, 1980; Blazek *et al.*, 1985). Because of the difficulty to detect *T. asiatica* during meat inspection, infected livers are likely to enter the food chain and infect humans, especially considering the local culinary habit to consume undercooked liver (Vien *et al.*, 2013).

On the other hand, we were not able to detect cysticerci of *T. solium* in any of the investigated tissues of 399 pigs raised in traditional farms. Interestingly, *T. solium* antibodies were detected in one serum sample, as determined by both LLGP-EITB and rT24H-EITB. This pig harboured many *T. hydatigena* cysticerci but, conversely, no *T. solium* cysticerci were detected. This result may be explained by the study procedures – that is, dissecting only the predilection organs, while cysticerci may have been located somewhere else in the carcass. Alternatively, the pig may have been exposed to *T. solium* eggs without establishing cysticerci (Conlan *et al.*, 2012; Devleeschauwer *et al.*, 2013). The possibility of cross-reactions with *T. hydatigena* in the LLGP-EITB and rT24H-EITB tests is less plausible in this case, as the serum reacted to the GP42 and GP50 bands in the LLGP-EITB while only the GP50 band has been found to be less specific (Gomez-Puerta *et al.*, 2019); and the GP50 is not included in the rT24-EITB.

This study revealed a high prevalence of *T. hydatigena* cysticercosis in pigs (18.0%, 95% CI: 14.5–22.1%), although lower than found in previous studies (25.1–31.8%) in pigs in Vietnam (Nguyen *et al.*, 2016). Similarly, in Laos, the occurrence of *T. hydatigena* (22.4%) is much more common than *T. solium* (0.8%) in pigs (Conlan *et al.*, 2012). The low prevalence of zoonotic cysticercosis might be the consequence of the improved general living conditions, hygiene and sanitation of the local populations. In contrast, conditions allowing the completion of the *T. hydatigena* life cycle persist in the region: the traditional backyard farming type is still prominent (Lapar *et al.*, 2012), allowing pigs to have access to faeces of dogs that are free-roaming and are often fed condemned organs, which may contain *T. hydatigena* cysticerci.

The study is also the first to report the presence of *S. erinaceieuropaei* in a pig in Vietnam. The literature on this parasite in pigs is limited; it was reported in pork from feral hogs in the US, but not in the liver (Bengtson & Rogers, 2001). *Spirometra erinaceieuropaei* is a zoonotic parasite causing sparganosis in humans. It has been identified in humans in Vietnam and other countries in Asia, such as Korea, China and Thailand (Anantaphruti *et al.*, 2011; Le *et al.*, 2017; Tang *et al.*, 2017; Kim *et al.*, 2018; Muigg *et al.*, 2019). This larva found in the pig was very small and, thus, could easily have been ignored during meat inspection. Humans or dogs and cats in the area may get infected by eating undercooked infected livers.

In this study, we used the B158/B60 Ag-ELISA on the collected pig serum samples. This test detects infection with viable *Taenia* cysticerci, and is genus- (not species) specific (Dorny *et al.*, 2004; Rodriguez-Hidalgo *et al.*, 2006). Consequently, pigs with either *T.*

hydatigena or *T. asiatica* infection were found positive. The high prevalence of *T. hydatigena* and the low prevalence of zoonotic cysticercosis in pigs in this study suggest that the Ag-ELISA is not suitable to diagnose zoonotic cysticercosis in Vietnam. This situation is different from some African countries where the specificity of Ag-ELISA test for *T. solium* was reported to be as high as 94.7% (Dorny *et al.*, 2004), because of the lower prevalence of *T. hydatigena* (Nguyen *et al.*, 2016), the absence of *T. asiatica* (Eom *et al.*, 2009) and the high to very high prevalence of *T. solium* in those regions (Dorny *et al.*, 2004).

In conclusion, *T. solium* cysticercosis was not found in pigs slaughtered in low-throughput abattoirs in this area by slicing predilection sites. Furthermore, *T. asiatica* was detected at a low prevalence in pig livers and was confirmed by molecular techniques. The prevalence of non-zoonotic *T. hydatigena* was high. Finally, results of serological techniques, especially the Ag-ELISA, to study the prevalence of *T. solium* in the area, should be interpreted with caution because of their low specificity.

Acknowledgements. The authors thank the District Station of Animal Health in Tan Son and Yen Lap, Phu Tho, a student team (Nguyen Van Toan, Hoang Thanh Truc, Can Quoc Hung) from the Faculty of Veterinary Medicine in National University of Agriculture and Dinh The Dung from the Vietnam-Russia Tropical Center for supporting the field work. The authors also thank their colleagues in the National Center for Veterinary Diagnosis, Hanoi, Vietnam.

Financial support. This work was supported by the Directorate General for Development, Belgium, through the individual PhD program (Man T.T. Nguyen) of the Institute of Tropical Medicine Antwerp, Belgium.

Conflicts of interest. The authors declare that there is no conflict of interest.

Ethical standards. The authors declare compliance with animal welfare and ethical guidelines of the investigators for all animal manipulations in this study.

References

- Anantaphruti MT, Nawa Y and Vanvanitchai Y (2011) Human sparganosis in Thailand: an overview. *Acta Tropica* **118**(3), 171–176.
- Bengtson SD and Rogers F (2001) Prevalence of sparganosis by county of origin in Florida feral swine. *Veterinary Parasitology* **97**(3), 241–244.
- Blazek K, Schramlova J and Hulinska D (1985) Pathology of the migration phase of *Taenia hydatigena* (Pallas, 1766) larvae. *Folia Parasitologica* **33**, 127–137.
- Conlan JV, Vongxay K, Khamlome B, Dorny P, Sripa B, Elliot A, Blacksell SD, Fenwick S and Thompson RCA (2012) A cross-sectional study of *Taenia solium* in a multiple taeniid-endemic region reveals competition may be protective. *American Society of Tropical Medicine and Hygiene* **87**(2), 281–291.
- De NV, Le TH, Lien PTH and Eom KS (2014) Current Status of taeniasis and cysticercosis in Vietnam. *The Korean Journal of Parasitology* **52**(2), 125–129.
- Devleeschauwer B, Aryal A, Tharmalingam J, Joshi DD, Rijal S, Speybroeck N, Gabriël S, Victor B and Dorny P (2013) Complexities in using sentinel pigs to study *Taenia solium* transmission dynamics under field conditions. *Veterinary Parasitology* **193**(1–3), 172–178.
- Dorny P, Phiri IK, Vercruyse J, Gabriel S, Willingham AL, Brandt J, Victor B, Speybroeck N and Berkvens D (2004) A Bayesian approach for estimating values for prevalence and diagnostic test characteristics of porcine cysticercosis. *International Journal for Parasitology* **34**(5), 569–576.
- Eom KS, Jeon HK and Rim HJ (2009) Geographical distribution of *Taenia asiatica* and related species. *The Korean Journal of Parasitology* **47**, 115–124.
- Eom KS, Rim HJ and Jeon HK (2020) *Taenia asiatica*: historical overview of taeniasis and cysticercosis with molecular characterization. *Advances in Parasitology* **108**, 133–173.
- Eom KS, Jeon H-K, Kong Y, *et al.* (2002) Identification of *Taenia asiatica* in China: molecular, morphological, and epidemiological analysis of a Luzhai isolate. *The Journal of parasitology* **88**(4), 758–764.
- Fan PC, Chung WC, Lin CY and Wu CC (1990) The pig as an intermediate host for Taiwan *Taenia* infection. *Journal of Helminthology* **64**(3), 223–231.
- Fan PC, Chung WC, Lin CY and Pawlowski ZS (1992) Experimental infection with *Taenia saginata* (Poland strain) in Taiwanese pigs. *Journal of Helminthology* **66**(3), 198–204.
- Food and Agriculture Organization (FAO) and World Health Organization (WHO) (2012) *Multicriteria-based ranking for risk management of food-borne parasites*. Microbiological Risk Assessment Series 23., WHO Press, Available at <http://www.fao.org/3/a-i3649e.pdf>.
- Gomez-Puerta L, Vargas-Calla A, Castillo Y, Lopez-Urbina MT, Dorny P, Garcia HH, Gonzalez AE and O'Neal SE (2019) Evaluation of cross-reactivity to *Taenia hydatigena* and *Echinococcus granulosus* in the enzyme-linked immunoelectrotransfer blot assay for the diagnosis of porcine cysticercosis. *Parasites & Vectors* **12**(1), 1–7.
- GSO (General Statistics Office of Vietnam. Statistical Data) (2019) Available at <https://gso.gov.vn/default.aspx?tabid=714> (accessed 22 January 2019) (in Vietnamese).
- Hall T (1999) BioEdit: a user-friendly biological sequence alignment program for windows 95/98/NT. *Nucleic Acids Symposium Series* **41**, 95–98.
- Huan LV (1994) *Parasitic helminths in pigs in several southern provinces and preventative measures*. Hanoi, National Institution of Veterinary Research (in Vietnamese).
- Kim JG, Ahn CS, Sohn WM, Nawa Y and Kong Y (2018) Human sparganosis in Korea. *Journal of Korean Medical Science* **33**(44), 1–15.
- Lan NTK, Quyen NT and Hoat PC (2011) Xác định tương quan giữa tỷ lệ nhiễm sán dây *Taenia hydatigena* trưởng thành ở chó và tỷ lệ nhiễm ấu sán *cysticercus tenuicollis* ở trâu, bò, lợn - thử nghiệm thuốc tẩy sán dây cho chó. *Veterinary Sciences and Techniques* **18**(6), 60–65 (in Vietnamese, with English abstract).
- Lapar MLA, Toan NN, Staal S, Minot N, Tisdell C, Que NN and Tuan NDA (2012) Smallholder competitiveness: insights from household pig production systems in Vietnam. International Association of Agricultural Economists (IAAE) Triennial Conference, Foz Do Iguacu, Brazil, 1–27.
- Le TH, Nga NB, van De N, Cong LD and Doanh NQ (2002) Phát hiện loài sán dây *Taenia asiatica* ký sinh trên người ở Việt Nam bằng phương pháp giám định sinh học phân tử. *Academia Journal of Biology* **24**(1), 23–29 (in Vietnamese).
- Le AT, Do LQT, Nguyen HBT, Nguyen HNT and Do AN (2017) Case report: the first case of human infection by adult of *Spirometra erinaceieuropaei* in Vietnam. *BMC Infectious Diseases* **17**(1), 1–4.
- Martin SW, Meek AH and Willeberg P (1987) *Veterinary epidemiology: principles and methods*. Ames, USA, Iowa State University Press, pp. 343.
- Michelet L and Dauga C (2012) Molecular evidence of host influences on the evolution and spread of human tapeworms. *BRV Biological Reviews* **87**(3), 731–741.
- Muigg V, Ruf MT, Schwarzkopf S, *et al.* (2019) Case report: human subcutaneous sparganosis in a Thai migrant. *The American Journal of Tropical Medicine and Hygiene* **101**(5), 1170–1173.
- Ng-Nguyen D, Stevenson MA and Traub RJ (2017) A systematic review of taeniasis, cysticercosis and trichinellosis in Vietnam. *Parasites & Vectors* **10**(1), 1–15.
- Ng-Nguyen D, Noh J, Breen K, Stevenson MA, Handali S and Traub RJ (2018) The epidemiology of porcine *Taenia solium* cysticercosis in communities of the central highlands in Vietnam. *Parasites & Vectors* **11**(360), 1–8.
- Nga NTD, Ninh HN, Hung PV and Lapar ML (2014) Smallholder pig value chain development in Vietnam: situation analysis and trends. Available at https://cgspace.cgiar.org/bitstream/handle/10568/53935/pr_situation_analysis_vietnam_web.pdf?sequence=7. (accessed 2 October 2020).
- Nguyen MTT, Gabriël S, Abatih EN and Dorny P (2016) A systematic review on the global occurrence of *Taenia hydatigena* in pigs and cattle. *Veterinary Parasitology* **226**, 97–103.

- Noh J, Rodriguez S, Lee YM, Handali S, Gonzalez AE, Gilman RH, Tsang VCW, Garcia HH and Wilkins PP** (2014) Recombinant protein- and synthetic peptide-based immunoblot test for diagnosis of neurocysticercosis. *Journal of Clinical Microbiology* **52**(5), 1429–1434.
- Polley LR and Mostert PE** (1980) *Ascaris suum* in Saskatchewan pigs: an abattoir survey of prevalence and intensity of infection. *Canadian Veterinary Journal* **21**(11), 307–309.
- R Core Team** (2020) *R: a language and environment for statistical computing*. Vienna, Austria, R Foundation for Statistical Computing.
- Rodriguez-Hidalgo R, Geysen D, Benítez-Ortiz W, Geerts S and Brandt J** (2002) Comparison of conventional techniques to differentiate between *Taenia solium* and *Taenia saginata* and an improved polymerase chain reaction restriction fragment length polymorphism assay using a mitochondrial 12 rDNA fragment. *Journal of Parasitology* **88**(5), 1007–1011.
- Rodriguez-Hidalgo R, Benitez-Ortiz W, Praet N, Saa L, Vercruysse J, Brandt J and Dorny P** (2006) Taeniasis-cysticercosis in Southern Ecuador: assessment of infection status using multiple laboratory diagnostic tools. *Mem Inst Oswaldo Cruz, Rio de Janeiro* **101**(7), 779–782.
- SDAH (Sub-department of Animal Health, Vietnam)** (2018) Available at <https://phutho.gov.vn/vi/tinh-hinh-kinh-te-xa-hoi-nam-2017-tren-dia-ban-tinh-phu-tho> (accessed 22 March 2020 (in Vietnamese)).
- Somers R, Dorny P, Geysen D, Nguyen LA, Thach DC, Vercruysse J and Nguyen VK** (2007) Human tapeworms in north Vietnam. *Transactions of the Royal Society of Tropical Medicine and Hygiene* **101**(3), 275–277.
- Tang THC, Wong SSY, Lai CKC, et al.** (2017) Molecular identification of *Spirometra erinaceieuropaei* tapeworm in cases of human sparganosis, Hong Kong. *Emerging Infectious Diseases* **23**(4), 665–668.
- Trieu HS** (2012) Nghiên cứu kiểu gen mầm bệnh lâm sàng, cận lâm sàng, kết quả điều trị sán dây *Taenia* spp và ấu trùng sán dây lợn trên bệnh nhân tại Viện sốt rét-Ký sinh trùng - côn trùng trung ương 2007–2010. PhD thesis, Hanoi University of Medicine (in Vietnamese).
- Trung DD, Praet N, Cam TDT, Lam BVT, Manh HN, Gabriäl S and Dorny P** (2013) Assessing the burden of human cysticercosis in Vietnam. *Tropical Medicine & International Health* **18**(3), 352–356.
- Tsang VCW, Brand JA and Boyer AE** (1989) An enzyme-linked immunoelectrotransfer blot assay and glycoprotein antigens for diagnosing human cysticercosis (*Taenia solium*). *The Journal of Infectious Diseases* **159**, 50–59.
- Vien HV, Thach DTC, Thuan LK, Dung DT, Tan HV, Duc NT and Tuyet TT** (2013) Thực trạng một số yếu tố nguy cơ liên quan nhiễm sán dây và hiệu quả biện pháp phòng chống tại xã Long Cốc, huyện Tân Sơn, tỉnh Phú Thọ. *Journal of Malaria and Parasite Diseases Control* **6**, 60–67 (in Vietnamese).
- Vietnam Livestock Production** (2018) Biểu đồ sản lượng thịt theo địa phương. Available at <http://channuoivietnam.com/bieu-do-thong-ke-san-pham-chan-nuoi/bieu-phan-bo-san-luong-thit-heo-2013/> (accessed 22 March 2020) (in Vietnamese).
- World Health Organization (WHO)** (2015) *Department of Control of Neglected Tropical Diseases: Assembling a framework for intensified control of taeniasis and neurocysticercosis caused by Taenia solium: report of an informal consultation*. Geneva, WHO Headquarters, 17–18 July 2014. Ed. B. Abela Ridder. (Accessed 2 October 2020).
- World Health Organization (WHO)** (2015) *WHO estimates of the global burden of foodborne diseases. Foodborne diseases burden epidemiology reference group 2007-2015*. World Health Organization, pp. 255. www.who.int (accessed on 2 October, 2020).