

## Minimally Invasive Microbiopsies as an Improved Sampling Method for the Diagnosis of Cutaneous Leishmaniasis

Gemechu Churiso,<sup>1,a</sup> Saskia van Henten,<sup>2,a</sup> Lieselotte Cnops,<sup>2</sup> Julia Pollmann,<sup>2</sup> Roma Melkamu,<sup>3</sup> Mulualem Lemma,<sup>1</sup> Amare Kiflie,<sup>1</sup> Helina Fikre,<sup>3</sup> Johan van Griensven,<sup>2</sup> and Wim Adriaens<sup>2</sup>

<sup>1</sup>Department of Immunology and Molecular Biology, University of Gondar, Gondar, Ethiopia, <sup>2</sup>Unit of Neglected Tropical Diseases, Department of Clinical Sciences, Institute of Tropical Medicine, Antwerp, Belgium, and <sup>3</sup>Leishmania Research and Treatment Center, University of Gondar Hospital, Gondar, Ethiopia

Current sampling methods to diagnose cutaneous leishmaniasis are invasive and painful. An alternative and minimally invasive microbiopsy device was evaluated in a diverse range of cutaneous leishmaniasis lesions in Ethiopia. Using polymerase chain reaction–based diagnosis, the microbiopsy outperformed the routine skin slit sample by detecting more patients while pain scores were significantly lower.

**Keywords.** cutaneous leishmaniasis; diagnosis; *Leishmania aethiopica*; sample collection.

Cutaneous leishmaniasis (CL) is a debilitating skin condition, caused by the bite of sandflies infected with *Leishmania* parasites. It has an estimated yearly global incidence of around a million cases in almost 100 endemic countries [1]. Typically, CL lesions are described as ulcers, but other presentations are more common in many parts of the world. In Ethiopia, *L. aethiopica* is the main causative species. It causes a wide spectrum of disease with severe CL forms such as mucocutaneous CL (MCL) and diffuse CL (DCL), while most lesions present as nodules, plaques, erythema, or crusts [2].

CL diagnosis typically relies on an invasive punch biopsy or skin slit sample (mostly followed by microscopy or polymerase chain reaction [PCR]), which is painful and can lead to complications such as bleeding and scarring. Less invasive sampling methods such as filter paper [3] and cytology brushes [4] have

been explored in the past years, but they are not suitable for nonulcerated and dry lesions.

Recently, a minimally invasive microbiopsy tool was developed (Figure 1). It penetrates the skin to a depth of 350 μm and absorbs blood as well as skin cell lysates, mimicking the sandfly bite [5]. It has been shown to detect *L. aethiopica* in a nonulcerated lesion of a single DCL patient [6]. In this proof-of-principle study, we further investigated whether this minimally invasive microbiopsy can be used as an alternative sampling device in combination with molecular detection for diagnosis of CL in diverse lesion types.

### METHODS

The study was conducted at the Leishmania Research and Treatment Center (LRTC) and embedded in an ongoing study on CL diagnosis (NCT03837431). CL-suspected patients were consecutively enrolled from April to November 2019 with the following criteria: age >18 years, not receiving CL treatment, and no comorbidity with visceral leishmaniasis and tuberculosis.

Topical EMLA cream (5% lidocaine/prilocaine) was applied on the lesion for 30–60 minutes, and after cleaning with alcohol, a microbiopsy prototype sample (Trajan Scientific and Medical, Ringwood, Australia, described by Lin et al. [5]) was collected by trained staff. Next, the microbiopsy device lancet was sterilely removed and stored at –80°C. Subsequently, the routine skin slit was collected in proximity of the microbiopsy collection site, smeared, and stained with Giemsa for microscopy. The self-reported pain score (scored 0–10) for the microbiopsy and skin slit sample collection was recorded.

DNA was extracted from the frozen microbiopsy samples and ambiently stored on skin slit slides using the LEV blood DNA extraction kit (Promega, Madison, United States) with the Maxwell 16 automate (Promega). After adding lysis buffer and proteinase K, the microbiopsy lancet and skin slit slide scrapings were incubated at 56°C at 400 rpm for 20 minutes and loaded into the Maxwell device according to the manufacturer's instructions. The eluted DNA samples were stored at –80°C.

Leishmania DNA was detected by a real-time PCR targeting the kDNA gene as previously described (Merdekios et al., manuscript in preparation) on the QuantStudio 5 cycler (Applied Biosystems, Waltham, United States). Positive results were expressed with cycle threshold (Ct) values and were called positive when detected (any signal <50 cycles) in 2 separate runs or “weakly positive” when positive in only 1 valid run. Positive and negative controls were included in each PCR run.

Data analysis was done in R, version 3.6.1, and figures were made in Graph Pad Prism, version 8.0. The performance of the microbiopsy was compared against skin slit with the Wilcoxon

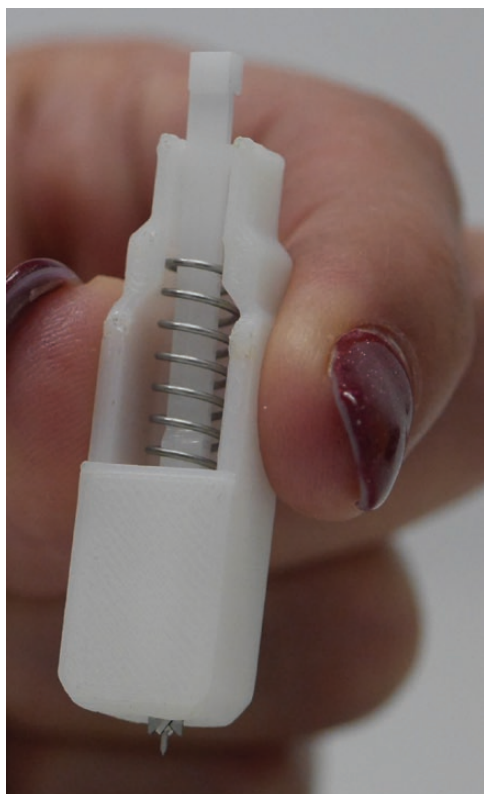Received 13 July 2020; editorial decision 10 August 2020; accepted 12 August 2020.

<sup>a</sup>Equal contribution

Correspondence: Saskia van Henten, MD, MSc, Unit of Neglected Tropical Diseases, Department of Clinical Sciences, Institute of Tropical Medicine, Nationalestraat 155, 2000, Antwerp, Belgium (svanhenten@itg.be).

Open Forum Infectious Diseases®

© The Author(s) 2020. Published by Oxford University Press on behalf of Infectious Diseases Society of America. This is an Open Access article distributed under the terms of the Creative Commons Attribution-NonCommercial-NoDerivs licence (<http://creativecommons.org/licenses/by-nc-nd/4.0/>), which permits non-commercial reproduction and distribution of the work, in any medium, provided the original work is not altered or transformed in any way, and that the work is properly cited. For commercial re-use, please contact journals.permissions@oup.com  
DOI: 10.1093/ofid/ofaa364



**Figure 1.** Picture of the microbiopsy device showing the 350- $\mu$ m lancet and the spring-loaded plunger mechanism. *Source:* Tarl Prow.

signed-rank test and the Spearman correlation coefficient, while Ct values over the different CL types were compared using the Kruskal-Wallis test.

#### Patient Consent Statement

The study was approved by the ethical review committee of the School of Biomedical and Laboratory Sciences, Gondar, Ethiopia, and ITM, Antwerp, Belgium. Written informed consent was obtained before sample collection.

#### RESULTS

A total of 29 clinically suspected CL cases was recruited, of which 14 (48.3%) were diagnosed as localized CL, 8 (27.6%) as MCL, and 7 (24.1%) as DCL (Figure 2A). Most patients were male (65.5%), of young age (median, 25.0 years), and presented with a single facial lesion (89.7%) of a median size of 6 cm (for detailed patient characteristics, see Supplementary Table 1). Lesions were mostly papulo-nodular (65.5%), swollen (58.6%), plaque (55.2%), erythematous (55.2%), and crusted (51.7%) (Figure 1A). Twelve patients had at least some ulceration (41.4%). The median lesion duration (interquartile range [IQR]) was 12 (6.0–24.0) months, and 4 cases had a prior CL history (13.8%).

With skin slit sample collection, 26 (89.7%) patients were confirmed for CL by PCR, of which 1 was weakly positive. With the microbiopsy, all 29 CL clinical suspects (100%) were

confirmed by PCR (with 1 weakly positive), suggesting an even higher sensitivity than PCR with skin slit collection (Figure 2B). The self-reported pain score was significantly lower for the microbiopsy (median [IQR], 2.0 [1.0–2.0]) compared with skin slit sampling (median [IQR], 6.0 [4.0–6.0];  $P < .001$ ).

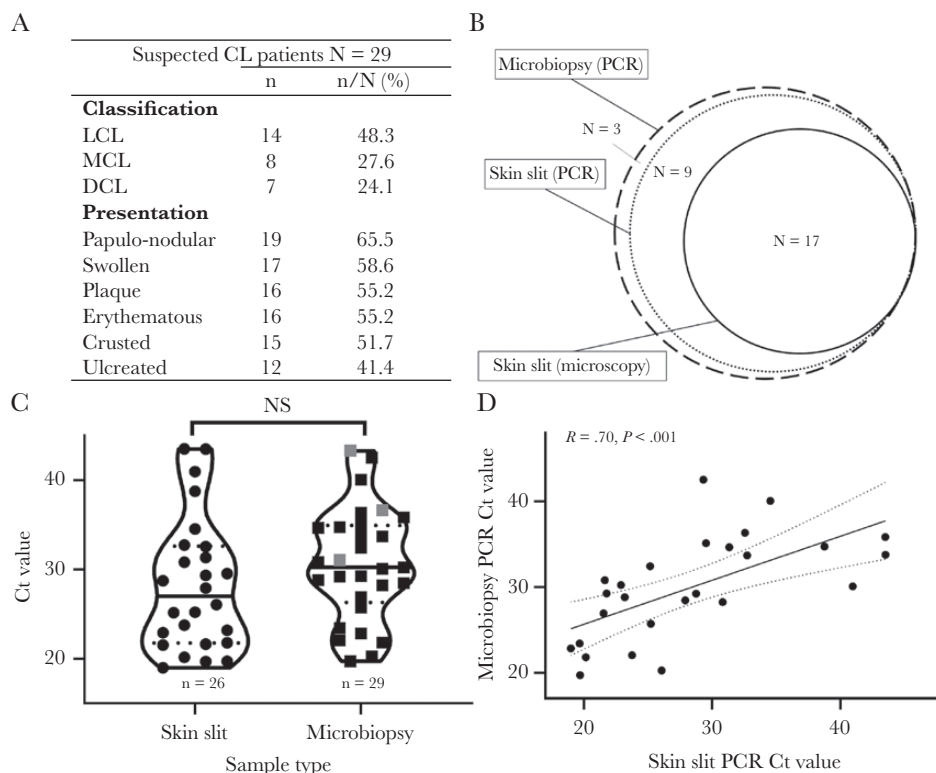
We semiquantitatively compared Ct values across both collection methods as a proxy measure for retrieved parasite load. There was no significant difference in Ct values of the skin slit (median [IQR], 27.0 [22.1–32.3]) and the microbiopsy (median [IQR], 30.2 [26.9–34.7];  $P = .143$ ) (Figure 2C), or between the different clinical presentations of CL ( $P = .363$  for microbiopsy and  $P = .971$  for skin slit). However, only a weak correlation in individual patients between collection methods was observed (Spearman  $R = .70$ ;  $P < .001$ ) (Figure 1D) but without a consistent bias in 1 direction, suggesting small but random variations in parasite DNA content.

#### DISCUSSION

Our findings suggest the minimally invasive microbiopsy as a promising alternative to invasive skin slit sampling for the diagnosis of CL patients. Despite its smaller sampling volume, it was able to capture sufficient parasite DNA in all lesion types, including nonulcerated and crusted lesions. Followed by molecular detection, it even outperformed routine skin slit sampling and confirmed the clinical diagnosis in all CL suspects.

In settings with well-equipped molecular platforms, the microbiopsy could be a more patient-friendly alternative for diagnosis and even species typing [6]. Additionally, the microbiopsy holds great promise as a research tool in clinical trials and longitudinal studies, allowing frequent sampling both in place (multiple samples per lesion or multiple lesions) and time (longitudinal follow-up). Although its implementation would be very relevant in routine care settings in low- and middle-income countries where the disease burden is highest, the time and cost of molecular diagnosis will still prevent its widespread use in routine diagnosis in rural areas and health centers. Therefore, it will be interesting to see whether microbiopsies can be used in combination with cheaper and faster techniques, such as microscopy or rapid diagnostic tests, or a quicker and easier molecular platform such as the loop-mediated isothermal amplification assay (LAMP).

We demonstrated no significant difference in Ct values between skin slit and microbiopsy sampling. In addition, patients with high Ct values in 1 sample type were consistently positive in the other sample type (with 1 exception). Surprisingly, 3 patients testing positive (of whom 1 had a high Ct value) after microbiopsy sampling were not confirmed on skin slits. This could be explained by the fact that parasites are optimally placed for transmission by sandfly bites, mimicked by the microbiopsy, and by the staining, which could have decreased detection rates on smears. Therefore, we considered them true positives, although contamination cannot be fully excluded.



**Figure 2.** A, Overview of lesion types and presentations of 29 CL suspected patients. B, Venn diagram depicting the number of positives with skin slit microscopy, skin slit PCR, and microbiopsy PCR. A total of 29 (100%) patients were positive for microbiopsy PCR, 26 (89.7%) were positive for skin slit PCR, and 17 (58.6%) were positive for skin slit microscopy. C, Violin plots for the comparison of cycle threshold (Ct) values for skin slit and microbiopsy samples tested with PCR. The 3 microbiopsy samples that were negative on skin slit are marked in gray. There was no significant difference between Ct values for microbiopsy and skin slit PCR ( $P = .143$ , Wilcoxon signed-rank test for paired samples). D, Correlation plot for microbiopsy and skin slit PCR Ct values ( $R = .70$ ;  $P < .001$ , Spearman correlation coefficient). Abbreviations: Ct, cycle threshold; DCL, diffuse cutaneous leishmaniasis; LCL, localized cutaneous leishmaniasis; MCL, muco-cutaneous leishmaniasis; NS, not significant; PCR, polymerase chain reaction.

Further research is required in the detection of asymptomatic *Leishmania* infection by PCR assays to establish clinical thresholds for diagnosis.

In conclusion, we argue that the microbiopsy sampling device is very promising for diagnosis of CL, as it is highly sensitive and patient-friendly, enabling multiple and frequent sampling for parasite load monitoring.

### Supplementary Data

Supplementary materials are available at *Open Forum Infectious Diseases* online. Consisting of data provided by the authors to benefit the reader, the posted materials are not copyedited and are the sole responsibility of the authors, so questions or comments should be addressed to the corresponding author.

### Acknowledgments

We would like to express our gratitude to all study participants for their participation. We thank all LRCT staff members involved in the collection of the data and the Drugs for Neglected Disease Initiative (University of Gondar) and the University of Gondar for their support. We would like to thank Kristien Cloots from the Department of Public Health at the Institute of Tropical Medicine and the original developer of the microbiopsy, Prof. Tarl Prow from the Future Industries Institute at the University of South Australia, for their kind support of the project and manuscript.

**Author contributions.** G.C., S.v.H., W.A., L.C., and J.v.G. contributed to the analysis and interpretation of the data. G.C., H.F., and R.M. collected

the data. W.A., L.C., and S.v.H. were responsible for the concept and design of the study. W.A., J.P., L.C., H.F., A.K., and M.L. supervised the study. G.C. and S.v.H. wrote the first draft of the article, with critical revisions from all other authors. All authors gave their final approval of the article.

**Financial support.** This work was supported by the Directorate-General for Development Cooperation and Humanitarian Aid (DGD), under the FA4 framework collaboration of the Institute of Tropical Medicine (Antwerp, Belgium) and the University of Gondar (Gondar, Ethiopia).

**Potential conflicts of interest.** The authors report no potential conflicts of interest. All authors have submitted the ICMJE Form for Disclosure of Potential Conflicts of Interest. Conflicts that the editors consider relevant to the content of the manuscript have been disclosed.

### References

- Alvar J, Vélez ID, Bern C, et al; WHO Leishmaniasis Control Team. Leishmaniasis worldwide and global estimates of its incidence. *PLoS One* **2012**; *7*:e35671.
- Fikre H, Mohammed R, Atinafu S, et al. Clinical features and treatment response of cutaneous leishmaniasis in North-West Ethiopia. *Trop Med Int Health* **2017**; *22*:1293–301.
- Boggild AK, Valencia BM, Espinosa D, et al. Detection and species identification of *Leishmania* DNA from filter paper lesion impressions for patients with American cutaneous leishmaniasis. *Clin Infect Dis* **2010**; *50*:e1–6.
- Valencia BM, Veland N, Alba M, et al. Non-invasive cytology brush PCR for the diagnosis and causative species identification of American cutaneous leishmaniasis in Peru. *PLoS One* **2012**; *7*:e49738.
- Lin LL, Prow TW, Raphael AP, et al. Microbiopsy engineered for minimally invasive and suture-free sub-millimetre skin sampling. *F1000Res* **2013**; *2*:120.
- Kirstein OD, Abbasi I, Horwitz BZ, et al. Minimally invasive microbiopsies: a novel sampling method for identifying asymptomatic, potentially infectious carriers of *Leishmania donovani*. *Int J Parasitol* **2017**; *47*:609–16.